

**PATIENT**

Bentley Lostkot

SPECIES

Canine

BREED

Chihuahua

SEX

Male Neutered

AGE

12.24.10

WEIGHT

8.7lbs

PRESENTING CLINICAL SIGNS

History: 1/2/23 suspect syncopal event. Grade 3/6 systolic murmur, left apex
 -Pertinent abnormal PE/Chem/CBC/UA Results: CK very mild increase 269 (10-200 U/L).
 Normotensive. Thx rads showed cardiomegaly with no evidence of pulmonary edema. ECG nsf.
 -Current medications: K9 Advantix.
 -Sedation used: Not required to complete full diagnostic ultrasound.
 -Pertinent previous ultrasound results: No previous.
 -STAT: Not requested
 CXR report: progressive cardiomegaly (mod), no CHF
 ECG report: NSR
 -Imaging performed by: Stephanie Warga RDCS, RVT.

ECHOCARDIOGRAM FINDINGS

2D, m-mode, color flow and doppler imaging is available. Diffuse thickening of mitral valve leaflets with minimal prolapse into the left atrial lumen. Mild to moderate eccentric mitral regurgitation with moderate left atrial dilation. Normal MR velocity. Minimal LV dilation with adequate myocardial function. The tricuspid valve appears mildly thickened with mild to moderate tricuspid regurgitation. TR velocity consistent with moderate pulmonary hypertension. Mild right atrial and ventricular prominence. MPA is normal. The pulmonic and aortic valves are normal in morphology and mobility. Normal pulmonic and aortic outflow velocities with laminar flow. No obvious aortic or pulmonic insufficiency. No pericardial or pleural effusion noted. No obvious cardiac masses.

CARDIAC CHART**INTERPRETED BY**

Maggie Machen Lamy,
 DVM, DACVIM
 (Cardiology)

HOSPITAL NAME

Perry Hall Animal
 Hospital

REFERRING VET

Dr. Hatzigiannakis

INVOICE

28377

DATE

1.17.23

CANINE CARDIAC PARAMETERS	MR VMAX (m/s)	TR VMAX (m/s)	LA/AO (Boon method)	LA/AO (Heart Base; Swe)	FS (%)	EF (%)	EPSS (cm)
NORMAL PARAMETER	4.5-5.5	<2.7	1.3	<1.6	28-40	40-100	<0.6
PATIENT	6.9	3.3	NM	1.7	47	80	NM
CANINE CARDIAC PARAMETERS	HR (BPM)	AV VMAX (m/s)	PV MAX (m/s)	BODY WEIGHT (kg)	LA 2D short axis Base view (cm)	LVIDd Avg; 2D and m-mode short axis (cm)	LVIDs Avg; 2D and m-mode short axis (cm)
NORMAL PARAMETER	50-100	0.7-1.7	0.7-1.6	BELOW	BELOW	BELOW	BELOW
PATIENT	120	1.1	1.0	3.9	2.0	2.9	1.6
*Normal chamber parameters expressed as a mean value (SD)				3	1.27 (5.3)	2.46 (2.46)	1.36 (5.5)
BODY WEIGHT DEPENDENT PARAMETERS				5	1.40 (4.5)	2.74 (5.2)	1.60 (4.7)
*Note: All measurements based upon multi-modal images and methods. An average value is reported.				10	1.50 (3.8)	3.27 (3.5)	2.06 (3.1)
				15	1.83 (2.0)	3.71 (2.4)	2.43 (2.1)
				20	2.02 (1.9)	4.14 (2.2)	2.80 (2.0)
				25	2.18 (2.4)	4.48 (2.9)	3.10 (2.5)
				30	2.33 (3.3)	4.83 (3.9)	3.39 (3.4)
				35	2.48 (4.3)	5.17 (5.0)	3.69 (4.5)
				40	2.62 (5.2)	5.48 (6.1)	3.96 (5.4)
				50	2.88 (7.1)	6.07 (8.3)	4.46 (7.4)

Adapted from June Boon, Veterinary Echocardiography, 1998
 Rishniw M and Hollis NE, J Vet Intern Med 2000; 14:429-435
 Hansson et al, Vet Rad and Ultrasound 2002
 Bonagura et al. Echocardiography: principles of interpretation, Vet Clin North Am 15:1177, 1995

INTERPRETATION OF THE FINDINGS & FURTHER RECOMMENDATIONS

Chronic degenerative valve disease causing mild to moderate mitral and tricuspid regurgitation. Moderate left atrial enlargement indicates the current risk for spontaneous congestive heart failure may be elevated in the future. Mild to moderate TR with mild pulmonary hypertension is also documented. The right heart supports this finding, with mild changes identified. No additional issues are identified.

The underlying genesis of PAH is poorly understood in cases other than heartworm infestation, though it occurs with increased frequency in a variety of forms of chronic lung disease and in patients with idiopathic pulmonary fibrosis. Primary PAH is also possible in certain breeds as well. If not performed, a heartworm antigen test is highly recommended.

Given the combination of MV disease, mild pulmonary arterial hypertension and a reported syncopal episode, recommend institute Pimobendan in this patient as below. Sildenafil is not yet indicated. Airway collapse is suggested on the CXR report, and if a cough is present this should also be addressed. It is important to note that the primary clinical sign of pulmonary hypertension is exertional dyspnea/syncope, not coughing, although a cough will certainly lead to worsening PAH. Monitoring for any clinical changes respiratory in origin is recommended. Prognosis is guarded given the combination of issues, and patient will always be at risk for progression to right or left-sided CHF, development of arrhythmias, collapse, etc going forward.

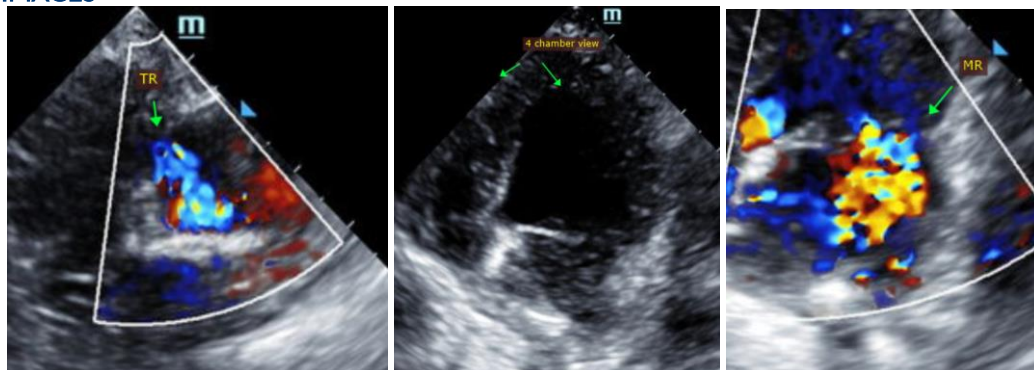
Once on Pimobendan for 3-5 days, anesthetic risk is considered mildly elevated. Cardiac protective drug choices (opioid/benzodiazepine premedication, propofol or alfaxalone induction, iso or sevoflurane gas) are recommended. **Pre-oxygenate 5-10 minutes prior to induction.** Monitor for arrhythmias, hypotension, and hypoxia both intra and post-operatively and intervene as necessary. Judicious IV fluid rates are recommended to avoid fluid overload. Avoid heart rate stimulating drugs such as atropine unless clinically indicated.

Omega fatty acid supplementation and mild salt restriction may also be of some long term benefit. Monitor for development of a progressive cough, labored breathing, exercise intolerance or collapse episodes.

Plan: Baseline BP recommended. Institute heart muscle support Pimobendan 0.3mg/kg PO q12h. Consider further cough treatment if indicated.

Recommend monitor for progression with a recheck echocardiogram in 6 months, sooner if any development of clinical signs.

IMAGES



The information and recommendations provided are based on the images presented by the referring veterinarian. No evaluation can be communicated regarding pathology that was not visible in the image/video clips provided.

Thank you for this referral. This report was generated using transcription software, and minor dictation errors may be present. If the clinical or image interpretation does not parallel your findings or if I can be of any further assistance please contact me.

Maggie Machen Lamy, DVM
Diplomate of the American College of Veterinary Internal Medicine (Cardiology)
info@sonopath.com